ANNALES
UNIVERSITATIS MARIAE CURIE-SKŁODOWSKA
LUBLIN — POLONIA
VOL. LV, 14 SECTIO D 2000

Department of Rehabilitation, University School of Medicine, Lublin
Klinika Rehabilitacji Akademii Medycznej w Lublinie

PIOTR MAJCHER, MAREK FATYGA, PIOTR GAWDA

Diagnosis of the patients with back pain, review of the concepts of aetiology of the back pain

Możliwości diagnostyczne u pacjentów z bólem dolnego odcinka lędźwiowego kręgosłupa

INTRODUCTION

Back pain is recognised as a common problem within community, and is know to affect general health. It is one of the main causes of disability. For many these are frequent episodes of acute pain with only temporary periods of disability.

Some of the patients with the back pain require immediate surgical treatment, some require acute inpatient rehabilitation, they need close medical monitoring, intensive rehabilitation nursing and comprehensive care provided by interdisciplinar medical team.

Most of them don't need such a comprehensive level of care. However all the patients with the low back require very careful physical and radiological evaluation.

ORGANIC CAUSES OF THE BACK PAIN

The reasons of the low back pain often remain doubtful.

Much effort is expended searching for a specific organic diagnosis such as a herniated lumbar spine, annular tears, spinal stenosis, spondylolisthesis, trauma, instability spine abnormalities, osteoporosis, inflammation of the bone or degenerative changes (Fig. 1, Fig. 2, Fig. 3, Fig. 4, Fig. 5, Fig. 6).

Abnormalities in the lumbar spine are common, and degenerative changes are founded in many cases. But correlation is poor between back pain and degenerative changes seen in radiographic and magnetic scans. Degenerative changes in the spine may consist of bony enlargement and osteophyte encroachment either into the spinal canal, causing central stenosis, or into the intervertebral foramen, leading to the foramina stenosis (Fig. 7, Fig. 8).

Figure 1. Displastic spondylolisthesis X-ray, sagittal view

Figure 2. Displastic spondylolisthesis MRI (disc prolapse)

Figure 3. Degenerative changes in scoliosis

Figure 4. Inflammation of the vertebrae

Figure 5. Post-traumatic instability, frontal view

Figure 6. Post-traumatic instability, sagittal view

Figure 7. Anatomo-patological sample of the spine. Foramina stenosis as a result of degenerative changes.

Figure 8. Anatomo-patological sample of the spine. Bastrup disease.

Ever since disc herniation was described as a potent cause of back trouble. Undoubtedly there are some patients who have nerve root distribution with clear evidence of dural tension with limited straight leg raising and specific neurological signs. Many however don't meet these criteria. Without such unequivocal evidence it is still common to incriminate a herniation seen on magnetic resonance imagining if it coincides with the distribution of symptoms but to ignore if it does not. Many patients probably undergo inappropriate surgery for that reason. It has to be stressed that other disc lesion give rise to chronic pain. The facet joints are another potential source of the back trouble. Osteoarthritis in peripheral joint give rise to symptoms, so why not in the spine? Each facet joint is innervated by more than one nerve root. (Fig. 9)

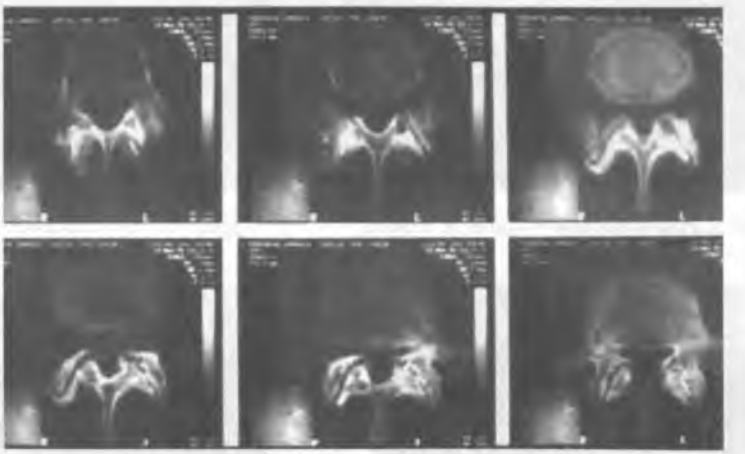

Figure 9. CT scans — spondyloarthrosis of the facet joints

FUNCTIONAL CAUSES OF THE BACK PAIN

But in the vast majority of cases it is impossible to identify the source of the pain. They are explained as an abuse of the intervertebral articulations of the L4–L5–S1 region.

The erect posture is that of the mild lordosis supported on an oscillating sacrum. The commonest causes of static low back is an increase in lumbar lordosis, and the history is that of low back pain after prolonged standing.

Examinations reveals a lordotic posture and the symptoms can be accentuated by passively hyperextending the patient's low back. Relief of the pain by lumbar flexion is supported evidence.

Kinetic back pain may be seen in the person who bends, stoops and lifts improperly. Normal forward flexing includes a reversal of the lumbar lordosis with a simultaneous rotation of the pelvis about the hip joints. This movement is restricted by soft tissue limitation, such as tight muscles, ligaments and fascia. The back can became painful due to this inflexibility. The history is of the low back after prolonged repeated flexion.

The examinations reveal the failure of the back to properly reverse its lordosis and simultaneously rotate the pelvis around the hip joint. The most common cause of kinetic low back pain, however, is faulty bending in the act of lifting. In this particular instance the patient has lifted either with the legs unflexed or has return to the erect position by prematurely reassuming the lordosis before the pelvis is totally derotated around the hip joint. This faulty mechanism may result in low back pain.

Low back pain can result from stress upon the ligaments and muscles of the posterior articulations, stress by pressure upon the posterior longitudinal ligament, or from irritation of the nerves in their intervertebral foramina.

Combined lateral bending and hyperextension of the low back will compress the nerve roots as they emerge through foramina.

The examinations requires observing the spine in its attemted flexion and re-extension, performing test of straight leg raising and related root tension signs to determine the freedom of the nerve roots as they emerge through the lower intervertebral foramina.

CONCLUSION

Back pain remains the greatest challenge with the field of musculoskeletal medicine. Management of the patients with the back pain remains controversial.

Comprehensive evaluation of a patient with back pain involves elucidation of nociceptive, biomechanical and functional components of the pain.

In chronic pain patients only multimodal concepts of treatment seem to be successful as far as they take care of somatic, psychosocial, ergonomic and sport physiological aspects.

REFERENCES

1. *Adrent W.*: Ból krzyża. PZWL 1992.
2. *Żuk T.*: Biomechanika w patogenezie zespołów bólowych dolnego odcinka kręgosłupa u ludzi pracy. PZWL 1977.
3. *Rainille J., Ahern D.*: The association of the pain with physical activities in chronic low back pain. Spine 1992.
4. *Elliot AM, Smith BH*: The epidemiology of chronic pain in the community. Lancet 1999.
5. *Van Deursen DL, Lengsfeld M.*: Mechanical effects of conttinuous passive motion on the lumbar spine in seating. Journal of Biomechanics 2000.
6. *Senger A.*: Ortopedia i rehabilitacja Degi. PZWL 1983.

STRESZCZENIE

Dolegliwości bólowe kręgosłupa stanowią jeden z najistotniejszych problemów współczesnego społeczeństwa. Wśród nich wyróżnia się grupę populacji, u której możemy wykazać zmiany strukturalne będące przyczyną tych dolegliwości, używając aktualnie nam dostępnych metod diagnostyki obrazowej. Taka diagnostyka daje nam możliwości oceny i podjęcia decyzji co do dalszego postępowania leczniczego i usprawniającego.

Autorzy, w oparciu o materiał z Kliniki Rehabilitacji, prezentują przykłady jednostek chorobowych, z którymi współwystępują objawy bólowe kręgosłupa.