

<sup>1</sup>Experimental Teratology Unit of the Human Anatomy Department, <sup>2</sup>Clinical Pathomorphology Department, <sup>3</sup>Pediatric Lung Disease and Rheumatology Department, Medical University of Lublin

FRANCISZEK BURDAN<sup>1</sup>, JUSTYNA SZUMIŁO<sup>2</sup>, JAROSŁAW DUDKA<sup>2</sup>,  
AGNIESZKA KOROBOWICZ<sup>3</sup>, AGNIESZKA FRONCZEK<sup>2</sup>,  
ROBERT KLEPACZ<sup>2</sup>, ZBIGNIEW WÓJTOWICZ<sup>1</sup>

*Pancreatic morphology in pregnant rats exposed to DuP-697  
– the irreversible, highly selective cyclooxygenase-2 inhibitor*

At least two main isoforms of cyclooxygenase (COX) were found, i.e. constitutive (COX-1) and inducible (COX-2). The enzyme initiated prostanoid synthesis and its activity is inhibited or blocked by the specific reversible or irreversible COX inhibitors, also known as nonsteroidal anti-inflammatory drugs (NSAIDs). Since COX-1 is responsible for various housekeeping functions, the non-selective COX inhibitors that decrease the isoenzyme activity are responsible for a number of side-effects, especially affecting gastrointestinal, renal and reproductive systems, as well as other prostaglandin-related ones (1, 2). However, the constitutive expression of COX-2 was also found in some intestinal organs. It should be noted that high expression of this isoform is typical of various fetal tissues, and decreases rapidly after delivery. In mature tissues the highest expression of COX-2 is characteristic of macula densa, pancreatic islets and some structures of the central nervous system (1–5). Unlike COX-1, physiological expression and the function of COX-2 is still not completely understood.

In our previous study (3), COX-1 immunoeexpression in pancreas was limited to acinar secretory cells, while COX-2 was found in secretory cells of endocrine pancreatic islets, epithelial cells of pancreatic ducts and smooth muscle cells of blood vessels of pancreatic stroma. The present study was undertaken to evaluate effects of DuP-697 (5-bromo-2-(4-fluorophenyl)-3-[4-(methylsulfonyl)phenyl]-thiophene) – the irreversible, highly selective cyclooxygenase-2 inhibitor (6) – on the morphology and immunoeexpression of the constitutive and inducible cyclooxygenase isoforms in maternal rat pancreas.

#### MATERIAL AND METHODS

The study was conducted on sexually mature albino rats of Wistar CRL:(WI)WUBR strain and approved by the Local Bioethical Committee. All the animals were obtained from an accredited breeder (Warsaw-Rembertów, Poland), housed and maintained in an animal care facility. On mating days, females (weight 200–250 g) were placed in cages with males (5:2) for approximately 14 hours. The following morning, a vaginal smear was done to determine if copulation had occurred. The day when sperm was found was designated gestation day 1 (GD1). Sperm positive females were randomly selected to the drug-treated and control groups.

DuP-697 (Sigma Chemical Co., St. Louis, MO, USA) was intragastrically administered to pregnant Wistar rats ( $n=17/\text{group}$ ) once daily from 7 to 18 gestation day (GD), in different doses, i.e. 0.05, 3.5 and 35.0 mg/kg/dose. Animals in control groups received the Tween 80 water suspension in a volume that corresponds to drug-exposed groups (10 ml/kg).

On gestation day 21, the animals were anaesthetized and blood was taken from the beating heart. The rats were killed by exsanguination. Internal organs were removed and examined. All the fetuses were teratologically examined, but the data are presented elsewhere (6).

The maternal pancreatic samples were fixed in 10% buffered formalin, embedded in paraffin, sectioned at 5  $\mu\text{m}$  and then stained routinely with hematoxylin and eosin (H&E).

Immunohistochemical reactions were performed on the 4  $\mu\text{m}$  slides obtained from the paraffin blocks used previously for histological examination. Primary monoclonal mouse anti-human antibodies against COX-1 and COX-2 (Novocastra; Newcastle, UK), as well as DakoEnvision<sup>TM</sup>+HRP. Mouse kit (DakoCytomation; Glostrup, Denmark) were used with 3',3'-diaminobenzidine tetrahydrochloride (DAB) (DakoCytomation; Glostrup, Denmark) as a chromogene. Details of the method were described elsewhere (3, 7). All the slides were evaluated, without knowledge of the treated-group, under light microscope (Olympus BX45; Tokyo, Japan).

## RESULTS

Histological structure of pancreas was found undisturbed in all the examined slides from both drug-exposed and control groups (Fig. 1).

Cytoplasmic COX-1 immunoreaction was observed in pancreatic acinar secretory cells (Fig. 2). Less intense reaction was found in Langerhans' islets. Unlike COX-1, cytoplasmic COX-2 was detected only in cells of endocrine pancreatic islets, epithelial cells of pancreatic ducts and endothelial cells of pancreatic stroma blood vessels (Fig. 3). Weak but nuclear staining was seen in acinar cells in some cases. No differences in both COX isoforms immunoeexpression were found between DuP-697-exposed and control groups.

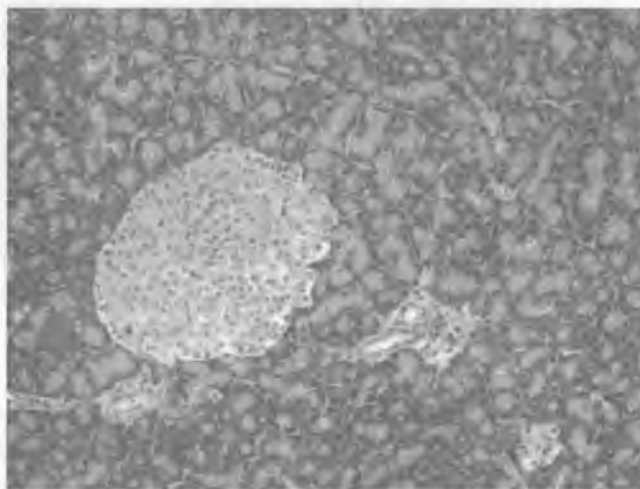


Fig. 1. Normal pancreatic morphology in rat exposed to the highest dose of DuP-697 (H&E, lens mag. x10)

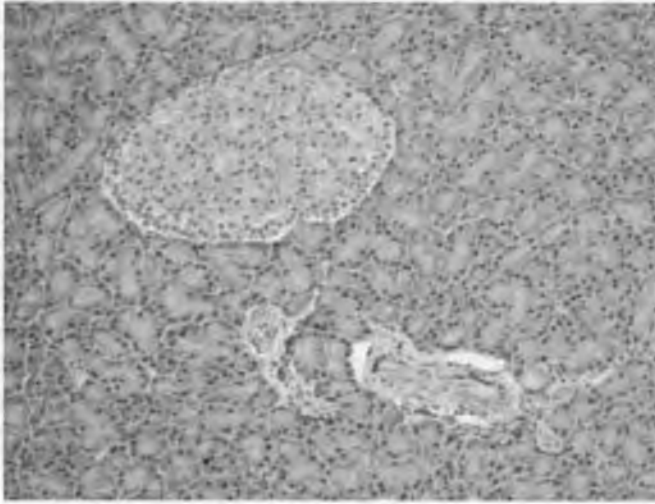


Fig. 2. Positive cytoplasmic immunostaining for COX-1 in pancreatic acinar and islet cells in rat exposed to the highest dose of DuP-697 (lens mag. x10)

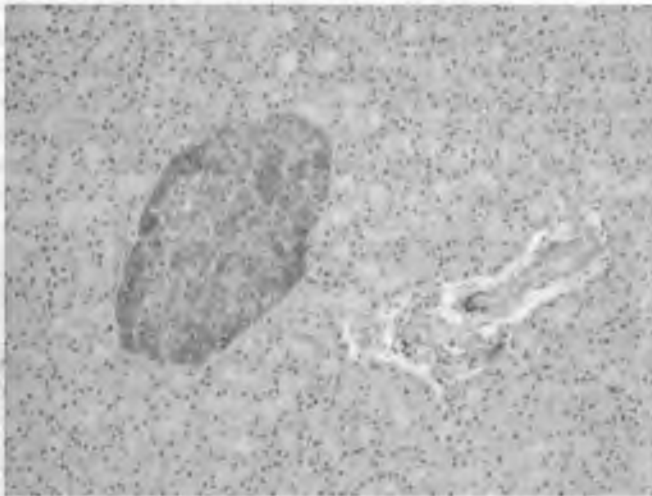


Fig. 3. Positive cytoplasmic immunostaining for COX-2 in pancreatic islet cells in rat exposed to the highest dose of DuP-697 (lens mag. x10)

## DISCUSSION

The study revealed that in spite of constitutive expression of inducible isoform in pancreas the organ morphology remained undisturbed after selective COX-2 inhibitor administration. The localization and immunoreactivity for COX-1 and COX-2 was the same as in pancreases taken from untreated male and male rats (3). The obtained data also verified previous experimental findings, concerning good tolerability of the tested compound. In the above cited paper by Burdan et al. (6), a good toxicological profile was proved. Dose-related embryo- and fetotoxicity was revealed only in

the group exposed to the highest dose (30.0 mg/kg) of DuP-697 that caused loss of COX-2 selectivity. According to the presented data the developmental toxicity was secondary to both maternal toxicity and inhibition of COX-1 isoform. Since DuP-697 is only an experimentally used compound, no similar human data were found in the available literature.

In the recently published article, it was proved that DFU – another selective COX-2 inhibitor – administered throughout mid and late pregnancy changed neither maternal nor fetal pancreatic morphology in rat, nor immunoexpression of both main COX isoforms in the organ (8). The toxicological profile of DFU was similar to DuP-697. It is worth to mention, that in spite of lack of teratogenicity and maternal toxicity (4, 9), intrauterine growth retardation (9) was observed only in the group exposed to the highest dose of the tested compound.

The role of prostanoid, especially prostaglandin E<sub>2</sub> (PGE<sub>2</sub>), and COX-related mechanism in etiology of diabetes mellitus and pancreatitis was already reported (10–17).

Histologically, inflammatory infiltration of Langerhans' islets is typical of type 1 diabetes, which recently has been classified as autoimmune disease (18). Additionally, inflammatory stimuli such as cytokines, liposaccharides and mitogens increase high physiological expression of COX-2 in insulin-secreting cells and besides, initiate their cytotoxicity. At the same time low physiological level of COX-1 did not significantly change (14). However, chronic hyperglycemia impairs insulin-secreting cells function and decreases the number and/or size of Langerhans' islets in type 2 diabetes. It may be the consequence of oversynthesis of interleukin 1 (IL-1) followed by apoptosis of insulin-secreting cells (16). The pioneer study coordinated by Hughes (15) indicated that recombinant human IL-1alpha was able to induce PGE<sub>2</sub> accumulation in isolated rat Langerhans' islets at concentrations similar to those at which the cytokine inhibits glucose-induced insulin secretion and islet glucose oxidation. Prior studies also showed that high glucose concentration increases COX-2 expression (17). The data were partially confirmed in mice treated with NS-398 – the selective COX-2 inhibitor – that avoided low-dose streptozotocin-induced diabetes (19).

It was also reported that COX-2 inhibition reduces severity of pancreatitis and pancreatitis-associated lung injury (10, 12, 13). Similar to our data, Alhan et al. (10) demonstrated that celecoxib did not change amylase activity, glucose level or other biochemical factors and pancreatic morphology in rat. It was also found that the treatment improves the lung and renal function and decreases the severity of pancreatic damage, at the same time normalizing the serum level of IL-6 in cerulean-induced pancreatitis in rats. Similar results were obtained in rats with taurocholate-induced acute pancreatitis treated with parecoxib (12). However, a case of celecoxib-induced acute pancreatitis and hepatitis was also revealed (11).

In conclusion, it was found that DuP-697 administered during pregnancy in rats changed neither maternal pancreatic morphology, nor immunoexpression of constitutive and inducible cyclooxygenase isoforms in the organ.

#### REFERENCES

1. Burdan F. et al.: Cyclooxygenase and prostanoids – biological implications. *Postępy Hig. Med. Dośw.*, 60, 129, 2006.
2. Fitzpatrick F. A.: Cyclooxygenase enzymes: regulation and function. *Curr. Pharm. Des.*, 10, 577, 2004.
3. Burdan F. et al.: Constitutive and inducible cyclooxygenase isoforms expressed in rat pancreas. *Annales UMCS, Sectio D*, 61, 572, 2006.
4. Burdan F. et al.: Gastrointestinal and hepatic toxicity of selective and non-selective

- cyclooxygenase-2 inhibitors in pregnant and non-pregnant rats. *Pharmacol. Res.*, 50, 533, 2004.
5. Streck R. D. et al.: Rat embryos express transcripts for cyclooxygenase-1 and carbonic anhydrase-4, but not for cyclooxygenase-2 during organogenesis. *Birth Defects Res. Part B, Dev. Reprod. Toxicol.*, 68, 57, 2003.
  6. Burdan F. et al.: Prenatal effects of DuP-697 – the irreversible, highly selective cyclooxygenase-2 inhibitor. *Reprod. Toxicol.*, 17, 413, 2003.
  7. Burdan F. et al.: Immunoexpression of the constitutive and inducible cyclooxygenase isoforms in maternal and fetal rats. *Annales UMCS, Sectio D*, 61, 330, 2006.
  8. Burdan F. et al.: Association of maternal pancreatic function and fetal growth in rats treated with DFU, a selective cyclooxygenase-2 inhibitor. *Folia Morphol.*, 66, 172, 2007.
  9. Burdan F.: Comparison of developmental toxicity of selective and non-selective cyclooxygenase-2 inhibitors in CRL: (WI)WUBR Wistar rats – DFU and piroxicam study. *Toxicology*, 211, 12, 2005.
  10. Alhan E. et al.: Effects of the celecoxib on the acute necrotizing pancreatitis in rats. *Inflammation*, 28, 303, 2004.
  11. Carrillo-Jimenez R., Nurnberger M.: Celecoxib-induced acute pancreatitis and hepatitis: a case report. *Arch. Intern. Med.*, 160, 553, 2000.
  12. de Almeida J. L. et al.: Inhibition of cyclooxygenase-2 in experimental severe acute pancreatitis. *Clinics*, 61, 301, 2006.
  13. Ethridge R. T. et al.: Cyclooxygenase-2 gene disruption attenuates the severity of acute pancreatitis and pancreatitis-associated lung injury. *Gastroenterology*, 123, 1311, 2002.
  14. Han X. et al.: Induction of cyclooxygenase-2 gene in pancreatic beta-cells by 12-lipoxygenase pathway product 12-hydroxyeicosatetraenoic acid. *Mol. Endocrinol.*, 16, 2145, 2002.
  15. Hughes J. H. et al.: Interleukin 1-induced prostaglandin E2 accumulation by isolated pancreatic islets. *Diabetes*, 38, 1251, 1989.
  16. Maedler K. et al.: Glucose-induced beta cell production of IL-1beta contributes to glucotoxicity in human pancreatic islets. *J. Clin. Invest.*, 110, 851, 2002.
  17. Shanmugam N. et al.: Increased expression of cyclooxygenase-2 in human pancreatic islets treated with high glucose or ligands of the advanced glycation endproduct-specific receptor (AGER), and in islets from diabetic mice. *Diabetologia*, 49, 100, 2006.
  18. Alm P. et al.: Morphological evidence for the existence of nitric oxide and carbon monoxide pathways in the rat islets of Langerhans: an immunocytochemical and confocal microscopical study. *Diabetologia*, 42, 978, 1999.
  19. Tabatabaie T. et al.: COX-2 inhibition prevents insulin-dependent diabetes in low-dose streptozotocin-treated mice. *Biochem. Biophys. Res. Commun.*, 273, 699, 2000.

## SUMMARY

Cyclooxygenase initiated prostanoid synthesis and its activity is inhibited or blocked by the specific reversible or irreversible inhibitors, also known as nonsteroidal anti-inflammatory drugs. The aim of the study was to evaluate effects of DuP-697 (5-bromo-2-(4-fluorophenyl)-3-[4-(methylsulfonyl)phenyl]-thiophene) – a selective COX-2 inhibitor – on the morphology and immunoexpression of the constitutive and inducible cyclooxygenase isoforms in maternal rat pancreas. The compound was administered (0.05–35.0 mg/kg) to pregnant Wistar rats once daily from 7 to 18 gestation day. Pancreas was examined histologically. Immunoexpression of COX-1 and COX-2 was evaluated. Histological structure of pancreas was found undisturbed. Cytoplasmic COX-

1 immunoreaction was observed in pancreatic acinar secretory cells. Less intense reaction was found in Langerhans' islets. Unlike COX-1, cytoplasmic COX-2 was detected only in cells of endocrine pancreatic islets, epithelial cells of pancreatic ducts and endothelial cells of pancreatic stroma blood vessels. Weak but nuclear staining was seen in acinar cells in some cases. No differences in COX immunoexpression were found in drug-exposed groups.

Morfologia trzustki u szczurów poddanych działaniu DuP-697 – wysoce selektywnego, nieodwracalnego selektywnego inhibitora cyklooksygenazy-2

Cyklooksygenaza jest enzymem inicjującym syntezę prostanoidów. Jego aktywność jest blokowana przez specyficzne odwracalne i nieodwracalne inhibitory, nazywane dawniej niesteroidowymi lekami przeciwzapalnymi. Celem pracy była ocena wpływu DuP-697 (5-bromo-2-(4-fluorophenyl)-3-[4-(methylsulfonyl)phenyl]-thiophene) – selektywnego inhibitora COX-2 – na morfologię oraz immunоекspresję formy konstytutywnej i indukowanej cyklooksygenazy u szczura w czasie ciąży. Preparat podawany był samicom szczura raz dziennie od 7 do 18 dnia ciąży. Oceniano obraz mikroskopowy trzustki. Immunоекspresję COX-1 i COX-2 wykrywano przy pomocy specyficznych przeciwciał. Morfologia narządu nie wykazywała istotnych zmian w żadnej z badanych grup doświadczalnych. Immunоекspresję COX-1 obserwowano w komórkach pęcherzykowych trzustki, natomiast reakcję przeciwko COX-2 stwierdzono w komórkach wewnątrzwydzielniczych wysp trzustkowych, komórkach nabłonka przewodów oraz miocytach naczyń krwionośnych. Nie stwierdzono różnic w immunoreaktywności obu izoenzymów między grupami narażonymi na DuP-697 i kontrolą.