

Dental Surgery Department, Medical University of Lublin

BARBARA DOBROCZYŃSKA-KREFTA, ANNA M. SZYSZKOWSKA

Odontoma – the cause of permanent teeth retention. Description of three cases

Odontoma belongs to the group of dentigenous tumors developing in jawbones in the stage of odontogenesis. According to the definition of WHO it is a congenital developmental defect, in which all kinds of dental tissue occur (9, 11). The exact etiology of odontoma is unknown, although it is suggested that the cause of its formation may be an injury, infection, or genetic factors (3, 4, 5, 7). Odontoma is the most frequently occurring dentigenous tumor and, according to various sources, it constitutes 22%, ca. 50%, and even ca. 75% of dentigenous tumors (3, 4, 7, 8, 10).

An odontoma can occur both in the jaw and in the mandible. It can develop in the region of retained teeth (ca. 50%), accompany an eruption cyst (ca. 10–15%), or supernumerary teeth (3, 4, 7). Odontomas sometimes occur in the maxillary sinus, palate, and even in the middle ear (2, 4, 5, 12, 13). There are also extraosteal odontomas, occurring in the soft tissues of oral cavity (4). Cases of the peripheral soft odontoma were reported (7), as well as the familial occurrence of odontomas, encountered in Gardner's syndrome and in Ekman–Westborg–Julin syndrome (1, 7, 11, 14). Most frequently changes occur singularly, although there is a report about the occurrence of multiple odontomas in facial skeleton of a 15-year-old Nigerian girl's skull (10).

Classification of odontomas, unified in the year 1970, comprises their 4 variants: ameloblastic fibroodontoma, odontoameloblastoma, mixed odontoma and composite odontoma. Depending on coherence, structure and type of texture, we distinguish soft odontomas – morphologically undifferentiated and immature, as well as hard odontomas – mature and differentiated (6). Histopathologically we distinguish the mixed odontoma, also defined as the complex odontoma, consisting of all the tooth tissues (enamel, dentin, cement and pulp) with almost normal structure, but atactically arranged, as well as the composite odontoma, containing all tissue elements of the tooth, but with a more ordered structure. A composite odontoma consists of numerous, more or less formed, with number ranking from a few to a few tenths, and even a few hundreds (6, 10). The development of odontomas is usually slow, asymptomatic, and, in most cases, these tumors do not transgress the limits of jawbones (11). The consequence of tumor growth can be deformation of alveolar process and disorder in the development of neighbouring teeth, e.g. abnormal position of neighbouring teeth, rotations, retention of a permanent tooth, persistence of a milk tooth. In the place, where an odontoma develops, usually no tooth is found in the dental arch (4, 8, 11). Lack of tooth in the dental arch after the period of its physiological eruption is an indication for radiological examination, which often reveals the presence of a tumor.

In a vast majority odontomas cause retention of a permanent tooth, very rarely these changes concern milk teeth, although cases of milk teeth retention due to the presence of an odontoma were described as well (3, 10). Large tumors often cause loosening and dislocation of teeth, sometimes disorders in permanent teeth eruption may cause neuralgias (3, 4, 10).

Treatment of odontomas is exclusively surgical and involves radical enucleation of the tumor, together with the capsule surrounding it, which prevents its recurrence and malignant transformation

(6, 7, 8, 11). In the forms of ameloblastic odontoma vast resection of jawbones is necessary, which is related to the nature of tumor with a clinical character similar to ameloblastoma. Final diagnosis and differentiation of particular kinds of odontomas, justifying radicalism of surgical procedures, are based on histopathological examination.

DESCRIPTION OF CASES

Case 1. Patient Sz. K., aged 8 years, turned up with a referral from an orthodontic outpatients' clinic in Lublin and the diagnosis of additional tooth buds in the region of tooth 11. The examination revealed crowding of teeth in the front section of the jaw and lack of tooth 11 in the dental arch. The dental film (Fig. 1) and radiovisiography (Fig. 2) revealed two additional formations inside a round lesion on the level of the crown of retained tooth 11. On the basis of radiological examination, the presence of an odontoma was found and the child was qualified for surgical procedure. In anesthesia with 2% lignocain with noradrenalin the tumor, surrounded by connective tissue capsule, was removed, together with 7 mini teeth, present in its light (Fig. 3).

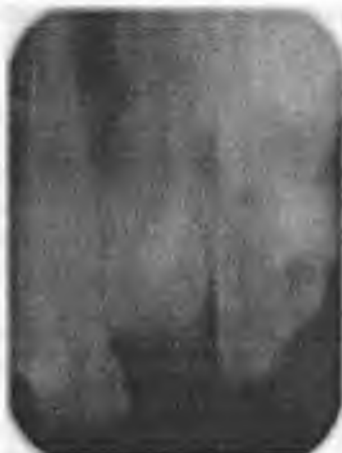

Fig. 1. Dental radiogram of tooth 11 region with a visible odontoma

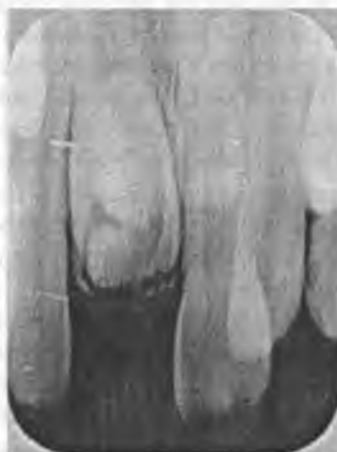

Fig. 2. Radiovisiography of an odontoma in the region of retained tooth 11 in an 8-year-old girl

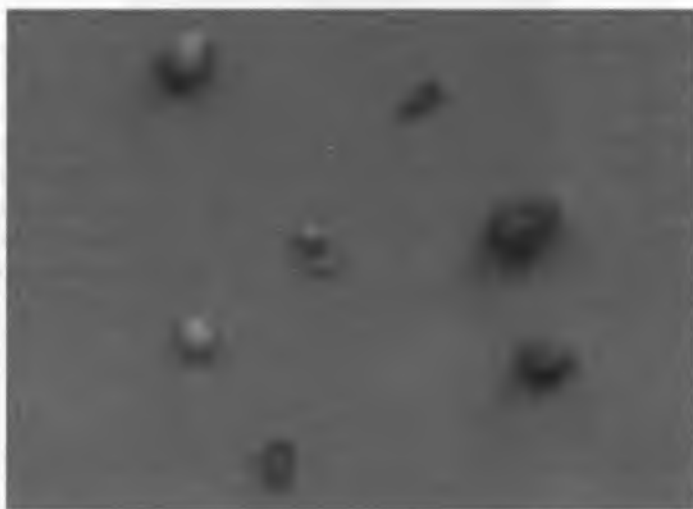


Fig. 3. Pseudo-teeth after tumor removal

Case 2. Patient J. P., 9 years old (as it was revealed by interview with the child's mother) came to a dentist's surgery because of abnormalities in eruption of permanent incisive teeth in the jaw. By clinical examination, the dentist found that teeth 21 and 22 are present in the dental arch, whereas on the right there were persistent milk teeth 51 and 52. The pantomogram, which the dentist advised to perform, revealed the presence of a tumor in the bone of dental process, under the crown of retained tooth 11 (Fig. 4). The presence of the tumor also caused abnormal position and hindered eruption of tooth 12. The dentist performed extraction of the milk teeth 51 and 52, as well as the surgical removal of the tumor. As after ten months permanent teeth still did not appear in the oral cavity, the anxious mother turned up for an orthodontic consultation with her child. Pantomogram (Fig. 5) and radiovisiography (Fig. 6) of the region of tooth 11 were performed once again and the tumor still could be found in the jaw. Therefore, the previously performed surgical procedure was not radical. On the basis of radiological evaluation the child was diagnosed with an odontoma in the jaw. A surgical procedure was performed again in local anesthesia with 2% lignocain with noradrenalin, removing the tumor together with the capsule. Inside the tumor there were 7 dental mini-formations of various sizes. Then, during the operation, the bone of the dental process was taken off and the crown of retained tooth 11 was denuded. On its surface an orthodontic retention element for elastic traction was installed to introduce the tooth into the dental arch. After two years of orthodontic treatment the effect of introducing tooth 11 into the dental arch was achieved.

Case 3. Patient B. J., 25 years old turned up with tooth 15 erupting in the oral vestibule. The tooth did not cause suffering any idiopathic aches, but there was pain on pressure in this region. By examination a slight, painful projection was found in the oral vestibule, above tooth 16. It was also observed that under pressure a purulent, cream-like exudate is delivered around the crown of the erupting tooth. The patient was referred for pantomogram (Fig. 7), which revealed tooth 15 retained in the bone, and around its crown sharply saturated shadows were visible. They corresponded to the x-ray image of an odontoma. Radiological examination was supplemented by radiovisiography and the patient was qualified for surgical procedure. On the day of the surgery a slight defect of mucous membrane was found in the oral vestibule, on the level of the crown of retained tooth. The patient reported that the day before he had noticed a fragment of tooth protruding from the mucous membrane

and "picked out" about 5 little formations, resembling little teeth. Despite this event the operation was not cancelled. In local anesthesia with 2% lignocain with noradenalin, after surgical denudation of the dental process bone in the region of tooth 15 the defragmented capsule of tumor was removed in total, together with a small, tooth-like formation. During the procedure the crown of retained tooth 15, situated very high, was denuded. Intraoperational evaluation and analysis of the roentgenogram suggested unfavourable position of the retained tooth 15, right under tooth 14. Therefore, it was very likely that tooth 14, tooth 13, nasal cavity and maxillary sinus would be injured during operation. Due to imminent complications, having consulted an orthodontist, a decision was made to save the retained tooth for observation and, in case of an ache, to extract tooth 14 and introduce the retained tooth 15 into the dental arch by means of orthodontic methods.

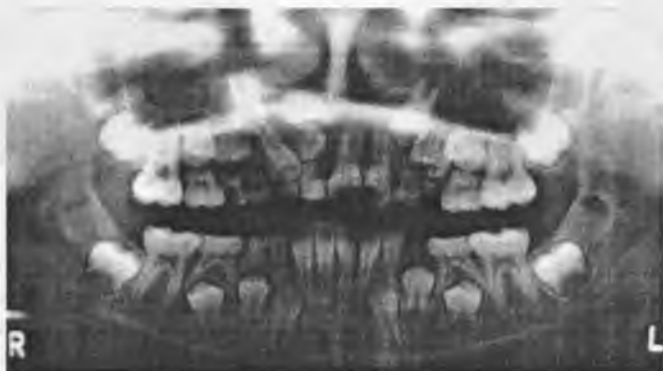

Fig . 4. Pantomogram with a visible odontoma at the retained tooth 11 in a 9-year-old girl

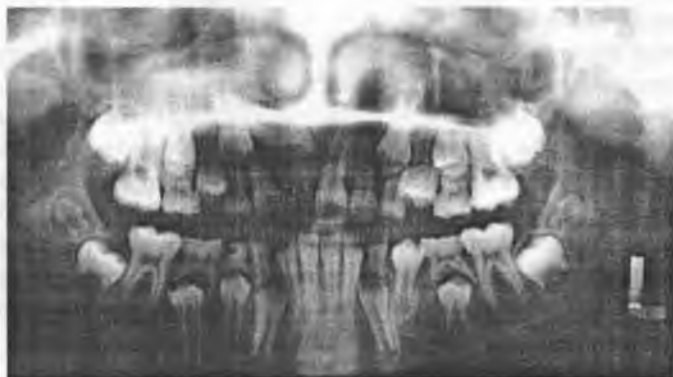

Fig. 5. Pantomogram 10 months after the first surgical procedure

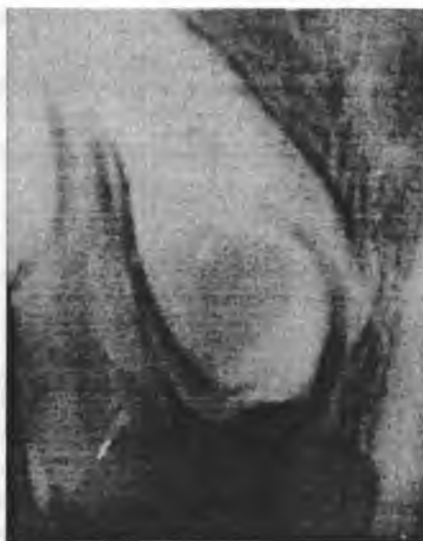

Fig. 6. Radiovisiography with a visible odontoma at the retained tooth 11 ten months after the first surgical procedure

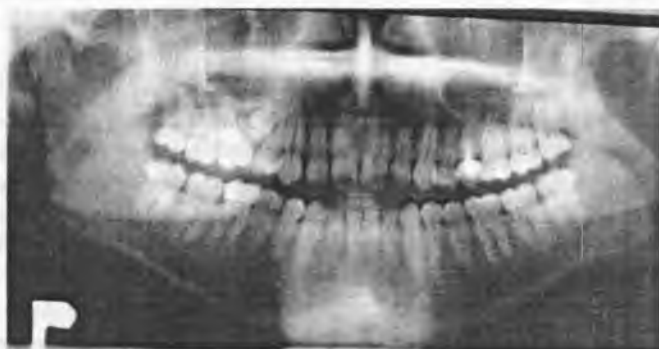

Fig. 7. Pantomogram of an odontoma at the retained tooth 15 in a 25-year-old patient

CONCLUSIONS

The presence of an odontoma often causes a permanent tooth retention. Odontomas are more frequently encountered in children in the interior section of the jaw. Early diagnosis of odontoma causing permanent tooth retention and removing it in childhood makes normal eruption of permanent tooth possible. Long lasting presence of an odontoma may cause deep retention of a permanent tooth in the bone, which leads to dental-occlusion complications.

REFERENCES

1. Bertoni F. et al.: Gardner syndrome. A report of 3 cases in members of the same family. *Minerva Stomatol.*, 181, 1990.

2. Belucci R. et al.: Odontoma of the middle ear: a case presentation 1975. Arch. Otolaryngol. Head Neck Surg., 1223, 2004.
3. Biedziak B. et al.: Zębiak i jego wpływ na powstawanie zmian w uzębieniu. Dent. Forum, 85, 2004.
4. Budkiewicz A. et al.: Zębiak – odontoma. Przegląd piśmiennictwa oraz postępowanie ortodontyczne. Mag. Stomat., 34, 2001.
5. Cabov T. et al.: Large complex odontoma of the left maxillary sinus. Wien Klein. Wochenschr., 780, 2005.
6. Cecherz Z. et al.: Zębiak jako przyczyna zatrzymania zębów stałych. Czas. Stomat., 114, 1986.
7. Dominiak M. et al.: Zębiaki. Lek. Wojsk., 49, 2000.
8. Janas A. et al.: Zębiaki złożone. Dent. Med. Probl., 425, 2005.
9. Kozarzewska M. et al.: Ząb zatrzymany i zębiak – opis przypadku. Nowa Stomat., 7, 1998.
10. Malara P. et al.: Zębiaki jako przyczyna zębów zatrzymanych. Czas. Stomat., 183, 2004.
11. Niedzielska I. et al.: Zębiak mieszany zuchwy. Czas. Stomat., 40, 2001.
12. Mupparapu M. et al.: Complex odontoma of unusual size involving the maxillary sinus: report of a case and review of CT and histopathologic features. Quintessence Int., 641, 2004.
13. Pogorzelska-Strączak B.: Zębiaki – przyczynek kazuistyczny. Mag. Stomat., 9, 1997.
14. Yoda T. et al.: Multiple macrodonts with odontoma in a mother and son – a variant of Ekman–Westborg–Julin syndrome. Report of a case. Oral Surg. Oral Med. Oral Pathol. Oral Radiol. Endod., 301, 1998.

SUMMARY

The paper is a short characterization of odontomas. It presents three cases of a permanent tooth retention caused by the presence of an odontoma. Two cases concerned children aged 8 and 9 years, in whom removal of the tumor allowed the permanent tooth 11 to erupt. In the third case – the tumor in an adult man caused deep retention of tooth 15 in the bone. Its removal would have been connected with many complications during a surgical procedure.

Zębiak – przyczyną zatrzymania zębów stałych. Opis trzech przypadków

Praca przedstawiająca krótką charakterystykę zębiaków opisuje trzy przypadki zatrzymania zębów stałych, spowodowane obecnością zębiaka. Dwa spośród nich dotyczyły dzieci w wieku 8 i 9 lat, u których usunięcie guza pozwoliło na wyróżnienie się 11 zęba stałego. W trzecim przypadku guz występujący u dorosłego mężczyzny spowodował głębokie zatrzymanie 15 zęba w kości. Jego usunięcie w wyniku zabiegu operacyjnego związane byłoby z wieloma komplikacjami.