

1st Department of Surgery and Transplantology, Medical University of Lublin
Department of Interventional Radiology and Neuroradiology, Medical University of Lublin
Department of Pathomorphology, Medical University of Lublin

KRZYSZTOF JANICKI, ELŻBIETA RADZIKOWSKA,
RADOSŁAW PIETURA, ZOFIA SIEZIENIEWSKA

*Pathophysiologic role of oxygen-free radicals
in toxic damage of the liver*

Oxidative stress, an unbalance in the peroxidant/antioxidant status of the cell that leads to potential damage, can participate at all the stages of the hepatocarcinogenic process. Oxygen free-radicals are also linked to inflammatory disease of the liver. During the past decade the developed concept was that mechanisms for chemical-induced hepatocyte death could be based upon oxidative stress. Inflammation, which is based on stress responses, has added dimensions to various types of liver injury. In terms of an oxidative stress component such disorders as: alcoholic liver disease, cholestatic liver diseases and metal storage diseases have been described (9).

A paradoxical phenomenon is, that oxygen so indispensable for the synthesis of high-energy phosphatase (ATP), under specific conditions can be cytotoxic to the whole organism. It is estimated that nearly 90% of the total O_2 consumed by mammalian species is delivered in mitochondria, where a four-electron reduction to H_2O by the respiratory chain is coupled to ATP synthesis (7). Nearly 2-5% of mitochondrial O_2 is incompletely reduced by leakage of electrons along the respiratory chain at forming reactive oxygen species such as superoxide, hydrogen peroxide, singlet oxygen, hydroxy radical (4). Oxygen is cytotoxic if oxygen concentration will be higher than its amount in the atmosphere. This phenomenon is called hyperoxidative process (5). Under normal conditions the described above situations are not observed. The loss of control of endogenous oxidative events related to the use of molecular oxygen by the cell is the major factor in oxidative stress injury. All tissues and cells contain systems for detoxication of biologic reactive intermediates and antioxidants to prevent or limit cellular damage due to oxidative stress events (9).

This study was undertaken to determine the influence of normobaric hyperoxide process on morphological changes in hepatic cells. In the present study we would be interested in knowing the answers to the key questions such as:

- Is there any dependence between the hyperoxide process and the morphological changes in the liver?
- What is the degree of dependence between the time of hyperoxide process and the observed liver's changes?

MATERIAL AND METHODS

Male Wistar-strain rats weighing 200-250g were used in all experiments. All the rats were given human care in compliance with institutional guidelines. The animals were fed ground chow *ad libitum*. The animals were subjected to reverse light cycling for 2 to 3 weeks before use. The middle dark point was set at 10 a.m. The rats were housed in standard laboratory cages (max 6 pieces per cage). After acclimation period, the animals were gathered in four experimental groups. The animals lived in typical environmental conditions and the rats breathed using atmospheric air. Inside the chamber as well as in the environment the average temperature was 23-25°C. The exposure time of the chemically pure oxygen was the base of the classifications of the rats into four experimental groups labelled as follows: I, II, III and the K (control group). The time of exposure was 12, 24 and 48 hours, respectively. The oxygen passed as constant-oxygen flow ventilation at the rate of 2 dm³ per minute. Oxygen concentration within the chambers was approximately 92%. It was measured using the Oxytest. Carbon dioxide concentration was determined using Capnograf. This concentration was less than 0.1%. The pressure within the chamber was analogous to barometric pressure.

The animals were dissected immediately after decapitation. Internal organs were investigated during autopsy. The whole liver was cut out. The fragments from the right central lobe and from the left lateral lobe of the liver were taken for histological examination. The specimens for electron microscopy were fixed in 4% paraformaldehyde plus 1.5% glutaraldehyde in 0.1mol/l phosphate buffer (pH 7.2). For electron microscopy the slices were washed overnight and post-fixed for 2 hours with osmium tetroxide in 0.1 mol/l cacodylate buffer (pH 7.4), dehydrated in increasing concentrations of ethanol, cleared in propylene oxide and embedded in Spurr's resin. Semithin and ultrathin sections were cut with a Reichert Cm-43 ultramicrotome. Semithin sections stained with methylene blue plus 1% Azure II in 15 sodium borate were examined in a Janowal Contrast Carl Zeiss-Jena electron microscope. Ultrathin sections were stained with uranyl acetate and lead citrate and examined in a Tesla BS-500 electron microscope.

Ultrastructural identification of different cell types required the examination of several sections from each block and careful examination of numerous selected photographs.

RESULTS

In the control group ultrastructural evaluation revealed the normal picture of both smooth and rough endoplasmic reticulum (SER and RER). The mitochondria with well developed cristae and electron dense matrix were distributed throughout the cytoplasm. Glycogen deposits were quite widespread throughout the cytoplasm. The numerous primary ribosomes and peroxysomes projected into the bile canaliculi. Occasionally, lipid droplets were visible.

After 12 hours the ultrastructural features were similar in all the animals and there were no significant modifications in comparison with the control group. The rough endoplasmic reticulum (RER) had become more extensive and the undilated aggregate of smooth endoplasmic reticulum was observed.

After 24 hours of the hyperoxide process the most prominent ultrastructural feature was the marked development of the cytoplasm. This was characterized by different ability of taking stain of the cytoplasm. Within the cytoplasm of numerous hepatocytes the vacuoles were noted. Numerous small lipid droplets were located in the hepatocytes cytoplasm. Occasionally, droplets were adhering to the nuclear membrane. The aggregates of smooth endoplasmic reticulum (SER) were well developed.

In some places, we studied the disturbances of microvilli of bile canalicules (Fig. 1). The injury of hepatocyte microvilli, especially in the space of Disse, was significant. The RER was located at the periphery of the cell adjacent to the plasma membrane, and also in the areas of mitochondria or in those of the nucleus. Sometimes the tubules of RER with the moderately electron dense material were dilated. Generally, the nuclei of hepatocytes and their nucleoli were normal and similar to the pictures observed in the control group. Sometimes, the nucleus was oblong or irregular with some indentations and peripherally located densely packed chromatin.




Fig. 1. Liver: The aggregates of smooth endoplasmic reticulum (SER).
The disturbances in microvilli of bile canalicules

After 48 hours of the hyperoxide process the observed pictures were similar to the features after 24 hours. Cytoplasmic vacuolization was detected histologically in periportal hepatocytes. Ultrastructurally, in some places the vacuoles were associated with a dilated and vesicularizing SER (Fig. 2). The nuclei of hepatocytes were similar to the nuclei observed in the above described group.

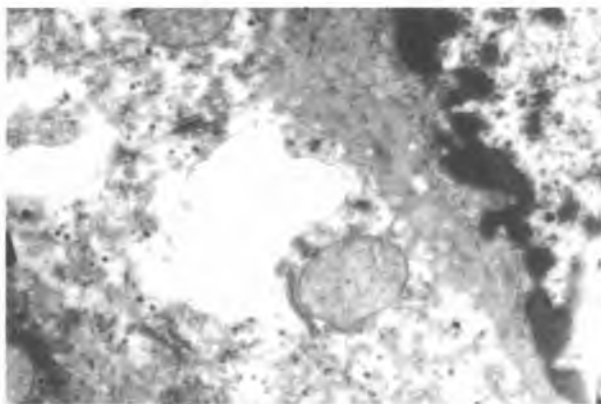


Fig. 2. Liver: The vacuoles associating with a dilated and vesicularizing SER

DISCUSSION

Free radicals have been implicated in over a hundred disease conditions in humans including hemorrhagic shock, atherosclerosis, ischaemia and reperfusion injury of many organs, gastrointestinal dysfunctions and carcinogenesis. The role of free radicals in liver's pathology has been underlined by many authors (1, 8, 9). They confirmed that a large number of natural and synthetic antioxidants have been demonstrated to induce beneficial effects on disease prevention. On the basis of experimental findings we can agree with others, that free radicals produced in biological systems may be important pathologic mediators in liver disease. The hepatic cells contain large amounts of such substances as: catalase (CAT), reduced glutathione (GSH), Cu-Zn superoxide dismutase (SOD), alfa-tocopherol, Mn-superoxide dismutase (Mn-SOD). In normal physiologic conditions, both enzymatic and nonenzymatic systems protect the hepatocytes due to the inactivations of free radicals (6).

The changes observed in histological pictures after 12, 24, and 48 hours of the hyperoxide process are of adaptative and temporary character. After 12 hours an increase of undilated cisterns of SER was observed. There is some evidence that the increase of SER can be connected with the inactivation of free radicals. The smooth endoplasmic reticulum arises from the rough endoplasmic reticulum into the degranulation process due to the loss of ribosomes. The degranulation process occurs in the normal liver and this process needs high-energy phosphates (ATP). During degranulation the ATP degraded to adenosine monophosphates and subsequently to hyperxanthine (3). In this study, the elements of degranulation of RER were observed. Furthermore, the observed elements of focal steatosis were the result of energetic deficiencies. One interpretation is that this bioenergetic deficiency has temporary character. The confirmation of this theory is the fact that more intensive steatosis was noted after 24 hours of experiment than after 48 hours. The intensified protein biosynthesis is the result of the intracellular hepatocytes regeneration. In addition to the described effects of protein biosynthesis, it can be said that focal aggregation of heterochromatin resulting in intracellular hepatocytes regeneration is smaller than in lesion of nucleus.

The obtained data suggest that the normobaric hyperoxide process may be responsible for parenchymal changes in the liver. These results apparently correspond to the data described in the literature (2, 8).

Chemical-induced hepatocyte cell death is always accompanied by an oxidative stress component. The formation of free radicals can be responsible for molecular lesions in the liver. The effects of the trials described above support the following conclusions: a) the normobaric hyperoxide process leads to ultrastructural adaptive changes of temporary character in the liver, b) the intracellular hepatocytes regeneration confirms the temporary character of the described hepatic changes, c) the hyperoxidative process causes no mitochondrial changes.

Free radicals work in concert to destroy lipids and thereby destroy the membrane. Usually, the degree of intensification of these changes is low. The present effects show that after 24 hours of the experiment, the lesions in microvilli in both the bile and vascular pole were noted. After 24 and 48 hours of the hyperoxide process the ultrastructural features of intensified protein's synthesis were observed. These changes were described as: dilatation of cisterns of RER with the fluculent and microgranular protein substance inside the lumen, open pores of the nuclear capsule, accumulation of heterochromatin in the area of the nuclear capsule. The latter phenomenon confirms the intensive exchange process between the nucleus and the cytoplasm.

CONCLUSIONS

1. The normobaric hyperoxide process causes morphological changes in the liver. They have adaptative and temporary character.
2. The observed processes of intracellular regeneration confirm the hypothesis that ultrastructural changes are reversible.

REFERENCES

1. B a c h n e r R.: Reduced Oxygen By-Products and White Blood Cells, Free Radicals in Biology. Academic Press, 6, New York 1982.
2. B i n d o l i A.: Lipid peroxidation in mitochondria. Free Rad. Biol. Med., 5, 247, 1995.
3. B o v e r i s A., C a d e n a s E.: Production of superoxide in mitochondria. [In:] Oberlay L. W., ed. Superoxide Dismutase II. Boca Raton: CRC, 15, 1982.
4. C a d e n a s E.: Biochemistry of oxygen toxicity. Annu. Rev. Biochem., 58,79,1989.
5. F r e e m a n B. A. et al.: Hyperoxia increases oxygen radical production in rat lungs mitochondria. J. Biol. Chem., 256, 10986, 1981.
6. G r a n d y S. et al.: Superoxide dismutase in human islets of Langerhans. New. Engl. J. Med., 304, 1547, 1981.
7. P r y o r W. A.: Oxy-radicals and related species: their formation, lifetimes and reaction. Ann. Rev. Physiol., 48, 657, 1986.
8. S a y p i l W. H. et al.: Free radical-induced liver injury. Effect of dietary vit. E deficiency on triacylglycerol level and its fatty acid profile in rat liver. Free Radic. Res. Commun., 14, 315, 1991.
9. S i e s H. Intraduction [In:] Sies H. ed. Oxidative Stress. Orlando: Academic Press, 1,1985.

2001.02.10

SUMMARY

The role of oxidative stress in toxic injury of the liver has been well documented. Molecular oxygen is indispensable for most of the living organisms but under specific conditions can be cytotoxic for all organisms. If oxygen concentration will be higher than its amount in the atmosphere, different pathological processes can occur in aerobic organisms. In normal hepatocytes, this physiologic oxidant stress is easily handled by mitochondrial defense. On the other hand, there are a lot of clinical indications to therapeutic application of both normobaric and hyperbaric hyperoxide processes. This work was undertaken to determine the influence of normobaric hyperoxide process on morphological structure of rat's hepatic cells. Furthermore, the aim of this study was to determine the degree of dependence between the time of hyperoxide process and morphological changes in the liver.

The experiment was conducted on 44 male Wistar strain rats with initial body weight of 230-250g. After acclimation period, the animals were gathered in experimental groups of 11 in a group. The exposure time of the influence of chemically pure oxygen was the base of the classification of

rats into experimental groups labelled as follows: I, II, III. The time of exposure was 12, 24 and 48 hrs, respectively. The control groups also contained 11 animals. The animals were dissected immediately after decapitation. The whole liver was cut out. Fragments from the right central lobe and from the left lateral lobe of the liver were taken. The histological preparations were evaluated in electron microscope.

In all the experimental groups adaptative and probably temporary histopathological changes were noted in the liver. The observed damages were probably reversible.

Patofizjologiczna rola wolnych rodników tlenowych w toksycznym uszkodzeniu wątroby

Stres oksydacyjny może powodować chemiczne uszkodzenie hepatocytów. Obecnie uważa się, iż wolne rodniki odgrywają decydującą rolę w patologicznych procesach zachodzących w organizmie. Tlen, który jest związkiem niezbędnym do życia organizmów, jest jednocześnie związkiem toksycznym. Skutki toksycznego działania hiperoksji są znane i udokumentowane od dawna. W organizmach aerobowych, poddanych działaniu stężeń tlenu wyższych niż w atmosferze, pojawiają się patologiczne zmiany, mogące prowadzić do wielu chorób, a nawet śmierci. Celem pracy była ocena zmian morfologicznych w wątrobie szczura, zachodzących pod wpływem normobarycznej hiperoksji. Badano również zależność między stopniem zaawansowania zmian a czasem trwania hiperoksji.

Badania przeprowadzono na 44 albinotycznych samcach szczura rasy Wistar o masie ciała 230-250g. Zwierzęta podzielono losowo na 4 grupy. Szczury grup I, II i III (po 11 szt.) były poddane ekspozycji czystego tlenu przez czas wynoszący odpowiednio 12, 24, 48 godz. Pozostałe zwierzęta stanowiły grupę kontrolną. Ocenę preparatów półcienkich i ultracienkich oraz dokumentację fotograficzną wykonano przy użyciu mikroskopu elektronowego BS-500 Tesla.

W preparatach półcienkich obrazy histologiczne wątroby zwierząt grupy kontrolnej były prawidłowe. Po 12 godz. hiperoksji obrazy były podobne. Po 24 godz. obrazy różniły się od grup I i kontrolnej nierównomiernym wybarwieniem się cytoplazmy hepatocytów. Obserwowano też różnej wielkości wodniczki w cytoplazmie wielu hepatocytów. Ultrastrukturalnie uwidoczniły się liczne drobne krople tłuszczu prostego. W nielicznych przypadkach obserwowano uszkodzenie mikrokosmków drobnych kanalików żółciowych i mikrokosmków w obrębie przestrzeni Dissego. Po 48 godz. obrazy histologiczne były podobne do grupy II. Obrazy ultrastrukturalne były również zbliżone. W niektórych preparatach obserwowano poszerzenie kanałów szorstkiej siateczki śródplazmatycznej (RER).

Normobaryczna hiperoksja wywołuje w wątrobie zmiany morfologiczne o charakterze zmian adaptacyjnych. Zmiany ultrastrukturalne są prawdopodobnie odwracalne, a potwierdzają to obserwowane procesy regeneracji wewnątrzkomórkowej.