

Katedra i Zakład Histologii i Embriologii z Pracownią Cytologii Doświadczalnej. Akademia Medyczna w Lublinie
Kierownik: prof. dr hab. n. med. Irena Królikowska-Prasał

Jadwiga ROMANOWSKA-SARLEJ

Effect of Estradiol Benzoate on the Morphology and Histochemical Changes in the Chick Gonads

Wpływ benzoesanu estradiolu na morfologię i zmiany histochemiczne w gonadach kurcząt

Влияние бензоата эстрадиола на морфологические и гистохимические изменения в гонадах цыплят

Sex hormones are believed to take part in the process of differentiation of the bird gonads (3, 4). This is based on the fact that estragens (7, 10, 13) and androgens (5) induce a sex reversal in the bird gonads. Injection of large amount of estrogen inhibits the functioning of the gonads due to the disturbance in gonadotropin secretion (8).

The purpose of this experiment was to analyze the effect of estradiol administered during the differentiation of the chick gonads upon the morphology and histochemical changes in the gonads.

MATERIALS AND METHODS

Experiments were performed on 120 chicken embryos (obtained from the Lublin Chicken Hatchery) which received into the yolk 0.15 μg of estradiol benzoate in 0.03 ml oil solution on the 7th day of incubation. The birds were divided into 3 groups: control group I, which received nothing, control group II, which received 0.03 ml of oil solution, and experimental group III, where the hormone was administered. On the day of hatching the left female gonad and both male gonads of the birds were taken for examination. The right ovary in the birds remains rudimentary and the responses to the hormon of the right and left male gonads are different. Sections of the gonads were stained with hematoxylin and eosin (H + E), with van Gieson method, after Brachet method for RNA and with Sudan III for lipids after Doddi. The material that was not fixed was used for a histoenzymatic reaction for the activity of 3- β -hydroxysteroid dehydrogenase (3 β HSD).

RESULTS

THE OVARY

Staining with H + E and after van Gieson

In control groups I and II the female gonads had a similar structure. The ovary was formed of two distinct parts: the cortex and the medulla (Fig. 1). The cortex formed a narrow margin with cords of germ cells and the surrounding, smaller prefollicular cells. The cytoplasm of the latter was intensely stained with H + E. Numerous germ cells with light and abundant cytoplasm contained enlarged nuclei with visible stages of division. The medullary part of the gonad, wider than the cortex, was characterized by interstices-cavities or lacunas and bundles of light interstitial cells. Cross-sections of blood vessels were found in their neighbourhood.

In the ovaries of the experimental animals more numerous germ cells in the stage of division were observed. The medullary part was diminished and the number of interstitial cells was reduced (Fig. 2).

Ribonucleic acid — RNA

In the germ cells purple granules corresponding to RNA occurred around the cell nuclei and the peripheral cytoplasm. More numerous RNA granules were observed in the pseudopodia of prefollicular cells. In the interstitial cells there were rare pyronine-absorbing granules around the cell nuclei. In the experimental animals more numerous RNA granules were found in the cytoplasm of prefollicular cells than in the control animals.

Lipids — Sudan III-staining

The presence of Sudan-absorbing substance was demonstrated in the medulla of the gonad. Large and small droplets with an intense orange colouring were found in the interstitial cells (Fig. 3). In the experimental group reaction to lipids was weakened due to a diminished amount of lipid droplets, the intensity of colouring remaining unchanged (Fig. 4).

3- β -hydroxysteroid dehydrogenase (3 β HSD)

A positive reaction to 3 β HSD was found in the interstitial cells as inten-

sely navy blue granules of formazans. After estradiol administration a distinct weakening of the enzyme activity was observed in those cells.

THE TESTIS

Staining with H + E and after van Gieson

The testes of control animals had a cylindrical shape. Their parenchyma contained seminiferous tubules and rather abundant intertubular tissue (Fig. 5). The population of tubules was made up of germ cells — spermatogonia and more numerous Sertoli cells. Rounded spermatogonia lay on the periphery or close to the tubules centre. They were separated by the Sertoli cells, which had a darker colouring. The intertubular tissue well vascularized, contained groups of light interstitial cells.

After estradiol was injected, the appearance of the left gonads was changed. They were larger than the right gonads, flattened and resembling the ovary. The staining demonstrated that there was a female cortex on their periphery, and often a subcortical, cavernous zone. The newly formed cortex had a structure similar to that of the control ovary and only very few germ cells were in the stage of division (Fig. 6). The remainder of the gonad had a canalicular structure with scanty interstitial cells.

Ribonucleic acid — RNA

The Brachet reaction to RNA in the spermatogonia of control gonads was intense and had a granular nature in the perinuclear zone of the cytoplasm. In Sertoli cells these granules were located near the base and apex of the cells. In the interstitial cells there were rare purple granules corresponding to RNA.

In the spermatogonia and Sertoli cells of the experimental animals more numerous pyronin-absorbing granules were observed than in the controls. In the cortex of the ovotestis the reaction was similar to that in the control ovary. The weakening of the RNA reaction was observed in the interstitial cells.

Lipids — Sudan III-staining

Reaction to lipids in the control testes was limited to interstitial cells. The weakening of reaction was observed in the experimental animals in those cells and single droplets of lipid were found inside the canalicles. In the subcortical part of the ovotestis the reaction was similar to that observed in the interstitial cells of the control ovaries.

3- β -hydroxysteroid dehydrogenase (3 β HSD)

The activity of the enzyme was manifested in its dominant form in the canalicular cells and smaller coarse-granular reaction occurred in the interstitial cells of the testis (Fig. 7).

In the experimental group the activity of 3 β HSD was weakened in the canalicles of both testes and rudimentary reaction was observed in the interstitial tissue.

DISCUSSION

The injection of female sex hormones into the hens eggs during incubation induces a characteristic reversal of male gonads, the degree of feminization depending on the amount of the agent used and the duration of treatment (13).

In the reported experiment, feminization of the left male gonads was observed, where the peripheral female cortex was found. In this part of the ovotestis and the cortex of experimental ovaries there were more numerous germ cells in the stage of division than in the control animals. It can be thus inferred that estradiol showed certain stimulating action upon the maturation of germ cells. Our observations have also been confirmed by other authors (2, 12). In the prefollicular cells and in the cells of seminiferous tubules the increased activity of RNA reaction was found, which indicates stimulated protein synthesis in their cytoplasm. Estradiol also showed its effect on the interstitial cells of the gonads, which was evident in their decrease in number. Similar results were obtained by G. C. Rennels (11) with young rats treated with estradiol.

In the present experiment there was a weakening of the enzyme activity of 3 β HSD in the interstitial cells, a drop in the RNA content and a disturbance of lipogenesis in the male gonads. On the other hand, A. W. Blackshaw (1), A. Limanowski (6), K. Miętkiewski et al. (9) observed hypertrophy of Leydig cells in the rat and the loss of all enzymatic capacity under the influence of estrogens.

The results of this experiment confirm the hypothesis that administration of estradiol produces changes in the morphology of and disturbs the function of the cells of birds gonads.

REFERENCES

1. Blackshaw A. W.: Histochemical Localization of Testicular Enzymes. [in:] *The Testis*, Ed. A. D. Johnson, Acad. Press. 2, 73, N. Y and London 1970.
2. Dahl E.: The Effects of Steroid on the Granulosa Cells in the Domestic Fowl. *Z. Zellforsch. Mikrosk. Anat.* 119, 179, 1971.

3. Haffen K.: Sexual Differentiation and Sexuality *in vitro*. [in:] Thomas J. A.: Organ Culture, Acad. Press., New York 1970.
4. Haffen K.: Sex Differentiation of Avian Gonads *in vitro*. Amer. Zool. **15**, 257, 1975.
5. Jordanov J., Angelova P.: Masculinisation des ovaries embryonnaires du poulet cultivés *in vitro* en parabiose avec des testicules embryonnaires. C. R. Acad. Bulg. Sci. **27**, 1447, 1974.
6. Limanowski A.: Zależne od wieku efekty stymulacji hormonalnej gonady męskiej szczura estrogenizowanego w pierwszych dniach po urodzeniu. Endocrinol. Pol. **19**, 257, 1978.
7. Łukina A.: Opriedielenije perioda czuwstwitelnosti połowych kletok kurinogo embrjona k' diejstwiju estradiol-bienzoata. Cytologia **20**, 903, 1978.
8. Miętkiewski K.: Wpływ estrogenów na przysadkę mózgową i układ płciowy szczura. Folia Morphol. **10**, 9, 1959.
9. Miętkiewski K., Łukaszczyk A.: Wpływ cyprotronu i dwuproponianu stilbestrolu na jądro szczura. Endocrinol. Pol. **20**, 415, 1969.
10. Narbaitz R.: Ultrastructural Aspect of Dortical Differentiation in Chick Ovaries and Intersexual Gonads. Z. Zellforsch. Mikrosk. Anat. **118**, 315, 1970.
11. Rennels G. C.: Influence of Hormones on the Histochemistry of Ovarian Interstitial Tissue in the Immature Rat. Am. J. Anat. **88**, 63, 1961.
12. Soszka S., Krawczuk A.: Badania doświadczalne nad wpływem gonadotropiny kosmówkowej i estradiolu na allogeniczny wszczep szczura białego. Endocrinol. Pol. **26**, 1, 1975.
13. Wolff F., Pinot M.: Stimulation du cortex de la gonade droite de l'embryon d'oiseau. Arch. Anat. Microsc. Morphol. Exp. **50**, 487, 1961.

Otrzymano 27 III 1987.

EXPLANATION TO FIGURES

- Fig. 1. Control ovary. Staining after van Gieson method. Magn. 280 ×.
 Fig. 2. Experimental group. Ovary. Staining after van Gieson method. Magn. 140 ×.
 Fig. 3. Control ovary. Staining after Sudan III. Magn. 280 ×.
 Fig. 4. Experimental group. Ovary. Staining after Sudan III. Magn. 280 ×.
 Fig. 5. Control group I. Testis. Staining H + E. Magn. 280 ×.
 Fig. 6. Experimental group. Ovotestis. Staining H + E. Magn. 280 ×.
 Fig. 7. Control group I. Testis. Activity of the 3βHSD. Magn. 280 ×.
 Fig. 8. Experimental group. Right testis. Activity of the 3βHSD. Magn. 280 ×.

STRESZCZENIE

Obserwowano zmiany morfologiczne i histochemiczne w gonadach kurcząt po podaniu 0,15 μg benzoesu estradiolu w okresie różnicowania gonad. Badania grup kontrolnych i zwierząt doświadczalnych przeprowadzono według ogólnie przyjętych metod histologicznych (barwienie H + E, metodą według van Giesona) i histochemicznych (wykrywanie: RNA, substancji tłuszczowych, aktywności 3βHSD). Stwierdzono, że estradiol podany zarodkom kur w okresie różnicowania gonad wywiera wpływ na morfologię i aktywność enzymatyczną komórek obu gonad.

РЕЗЮМЕ

Велись наблюдения за морфологическими и гистохимическими изменениями в гонадах цыплят после применения 0,15 μg бензоата эстрадиола в период дифференциации гонад. Исследование контрольных групп и опытных животных велись по общеприменяемым методам: гистологическим (окраска Н + С методом van Giesona) и гистохимическим (выявление RNA, жирного вещества, активности $3\beta\text{HSD}$). Определено, что поданный в период дифференциации гонад куриному эмбриону эстрадиол влияет на морфологию и энзиматическую активность клеток обеих гонад.




Fig. 5

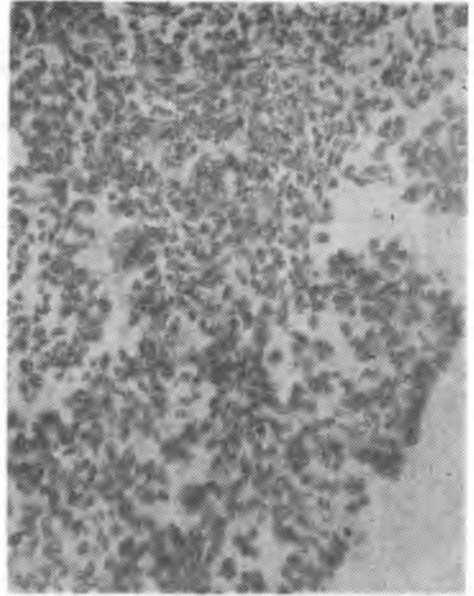


Fig. 6




Fig. 7

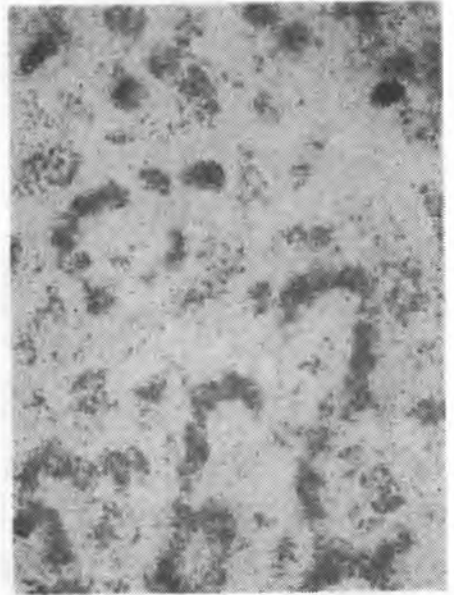


Fig. 8